

2017 January 10th

- **Riga 1st Hospital Radiology – Riga Latvia**
- **Criminal Fraud that shows all other MRIs are also Criminal Fraud →**

Riga 1st Hospital Radiology:

After being denied help in the US I flew to several countries in Europe and then finally landed in Riga, Latvia.

The full extent of the amount of neurological damage caused in a decade of medical mistreatment and negligence becomes elucidated in January 10th of 2017:

An MRI of the brain, cervical spine, and thoracic spine is ordered and completed by Dr. Inga Danilane at Riga 1st Hospital.

It shows gross neurodegeneration of the cervical spine and central inflammatory lesions in the cervical and thoracic spine that eventually cause neural atrophy and neurodegeneration (progressive multiple sclerosis).

But the doctors in the US didn't want to acknowledge the neurodegeneration so they directed the radiologist to erase any evidence of MS found in the MRI series. (The US had no limit in perpetuating negligence, they direct medical fraud in all foreign nations I was in). I recorded the radiology technician erasing MRI series data in this instance.

This recording is useful to show that the US not only directs medical falsifications and fraudulence in the US by erasing images in MRIs and writing false reports from them (along with other diagnostics), but that they have been instructing radiologists and doctors in foreign nations to erase and falsify data that show features of MS to perpetuate intentional physical harm.

It's the most unambiguous example of medical falsification with no chance of refutation.

**Video Recording of an attempt at Hiding Diagnostic Data for Multiple Sclerosis
(the full video is available)**

The screen shots from this video show how MRI series images are hidden or erased to hide a disease pathology or progression in MS.

This is from my January 10th 2017 MRI and it shows how the radiologist identifies a typical feature of a "T2 central inflammatory lesion" characteristic of multiple sclerosis in the upper spinal column and lower part of the thoracic column of the spine.

The radiologist then limits the MRI so it doesn't record the entire axial plane of the thoracic to try and hide the disease process.

This was done in previous MRIs in the US in Massachusetts as well which is why I recorded the series being erased in this instance.


The typical routine in the US is either erase the MRI series or hide the image planes that show the features of MS. Erasing planes or limiting a MRI series is easy to do so for any radiological technician.

It becomes additive when MRI images are erased and MRI reports are falsified from incomplete MRI series.


The radiologist identifies the lesion indicative of MS in the lower thoracic spine in the MRI being taken:




The radiologist then identifies the central lesions indicative of MS in the upper thoracic spine in the MRI being taken:



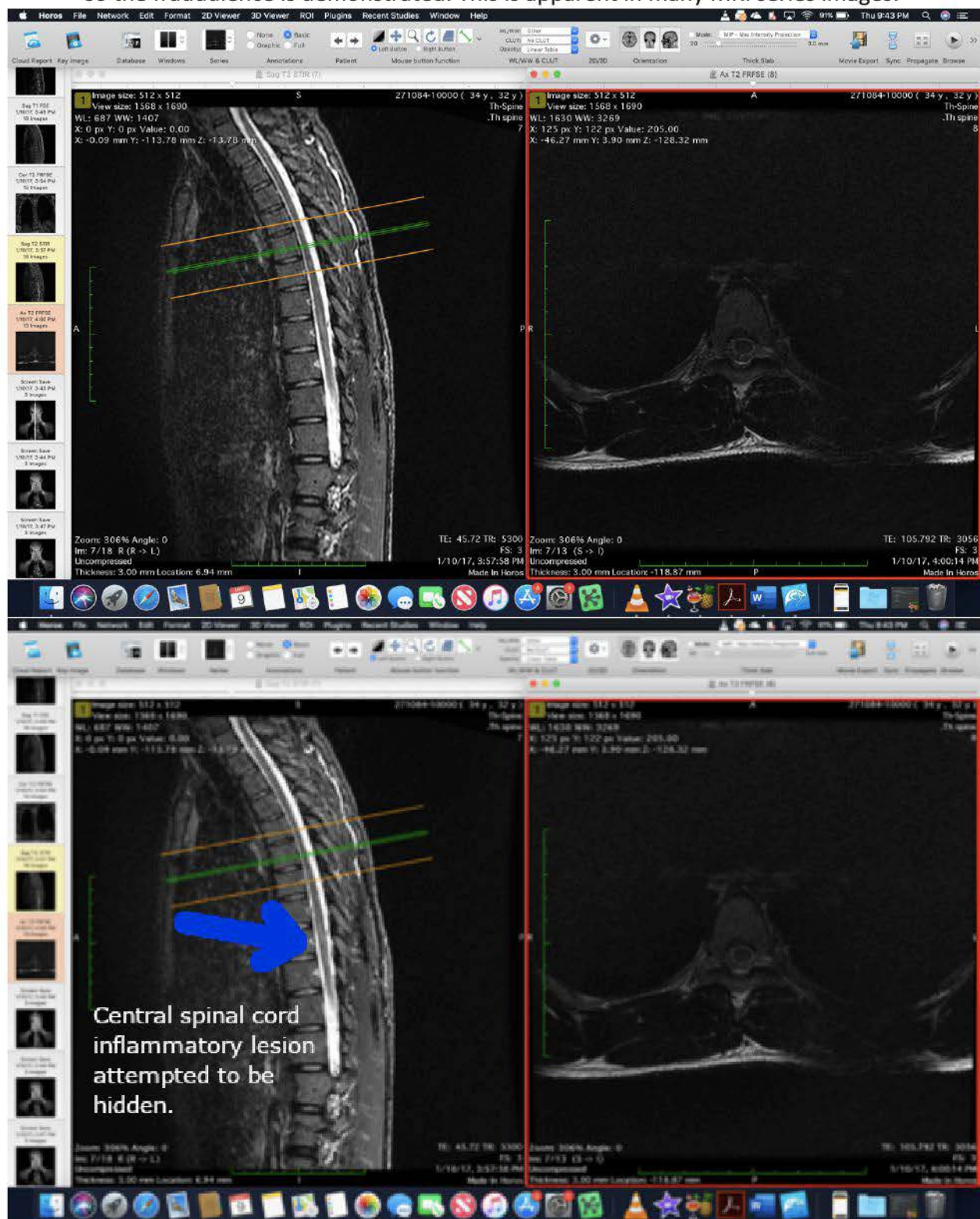
The radiologist then limits the MRI machine to not record the full axial plane that would show the lesions in the MRI:



The machine is automated now so she leaves:



The resulting MRI has a limited axial plane the doesn't include the features of the central lesion, so the fraudulence is demonstrated. This is apparent in many MRI series images:



The resulting MRI report is also fraudulated. This is also the typical method of fraudulating MRI data in the US (but full sets of images are erased, sometimes hundreds of images) and then writing falsified reports from it. All the MRI reports are falsified in my case, which eventually results in a progressive form of MS where the condition becomes undeniable.

In September 19th 2018, Dr. Eric Williamson (who also perpetuated medical negligence) mentions the limited axial plane of the MRI in his medical report. That means that due to radiologist limiting the axial plane he is unable to see the quality of the lesions. The lesion causes further neurodegeneration of the lower spinal column (signs of atrophy) in future MRIs:

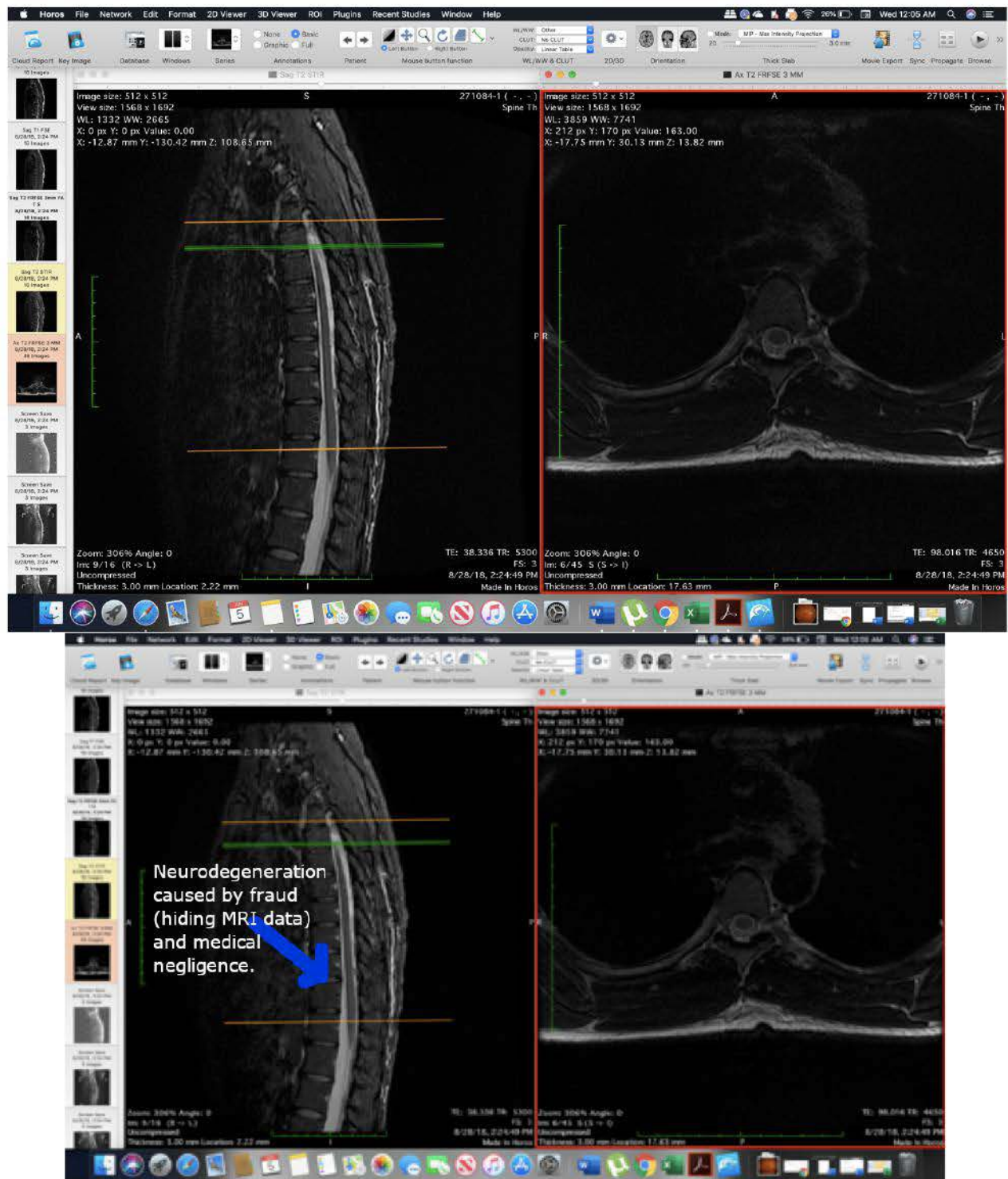
which similarly shows subtle central intensity - more apparent than any in the c spine yet only visible on sagittal pictures and not seen on limited axial slices that do not show any abnormality nor extend low enough to examine the suspected finding on t spine study. Despite all the reported findings, he says he had no follow

The radiologist limited the MRI machine to only the section that doesn't show abnormality, missing the upper and lower spine. She recognized the disease and pathology as the images were being recorded.

Nonetheless there is another way of showing the full axial plane of the spine, repeat the MRI using the same MRI machine later (its called "sequentializing" a MRI). Its given below to shows the extent of the crime:

In comparison what does a full image that isn't erased look like?

In August 28th 2018 I returned to the MRI clinic in Riga 1st Hospital and repeated the MRI. The fully axial plane of the MRI using the exact same MRI machine looks like this. What were central lesions are now regions of neurodegeneration due to negligence by August 28th 2018, its easy to demonstrate medical progression as well using MRI data.



This radiologist and many other radiologists perpetuated fraud in an attempt to hide evidence of multiple sclerosis to try and further the progression of multiple sclerosis.

This appearance of central lesion and then a sign of neurodegeneration also negates a future doctor's and radiology clinics attempt at intentionally misrepresenting features of progressive neurodegeneration as osteopathic "disk degeneration". This was attempted by Dr. Pia Schumacher in Berlin, Germany in a ER setting to withhold immediate emergency medical treatment for MS and the CI3M MRI clinic in Mexico City, Mexico for repeatedly writing falsified MRI reports in a gross and clear way over several MRIs taken in the clinic.