

## Figure 7 – EEG Test Report is likely Falsified

EEG Report from September 18<sup>th</sup> 2019.

Its undetermined if the report is accurate but considering the presence of easily detectable spikes in the EEG, I would most likely be in an interictal state.

<p style="text-align: center;">University College London Hospitals <b>NHS</b> NHS Foundation Trust</p> <p style="text-align: center;"><small>Department of Clinical Neurophysiology The National Hospital for Neurology and Neurosurgery Queen Square, London, WC1N 3BG Tel: (020) 344 34702 Email: UCLH.Neurophysiology@nhs.net Website: www.ucl.ac.uk/ncp</small></p> <p>EEG Investigation on 18/09/2019 Narendra JANA, DOB 27/10/1984 (34years) (UCLH: 21089233; NHS: 7216026954)</p> <p><b>Conclusion</b> The EEG is within normal limits. There are no epileptiform abnormalities and no other diagnostic features.</p> <p><b>Clinical Abstract</b> From referral: Dubious diagnosis of both MS and epilepsy. Referred to epilepsy clinic. ? Epileptiform changes</p> <p>From patient: Right handed - had breakfast - 5 hours sleep</p> <p>Medications: none. FMIH: none.</p> <p><b>Neurophysiology findings</b></p> <p>This routine recording was performed in the Department of Clinical Neurophysiology.</p> <p>The patient was alert and co-operative.</p> <p>The awake recording showed a well formed, well sustained and symmetrical 8-9Hz, up to 63µV, alpha rhythm which was seen over the posterior regions. This was reactive, attenuating upon eye opening and mental activation. Small amount of low amplitude 16-20Hz beta activity was seen over the fronto-central regions bilaterally.</p> <p><b>Sleep Findings:</b> The patient did not sleep, nor become drowsy.</p> <p><b>Activation procedures:</b> Overbreathing was performed well for three minutes and produced no EEG changes. Intermittent photic stimulation was performed using frequencies between 1-60Hz and elicited symmetrical following responses between 8-15Hz. No adverse responses were seen.</p> <p><b>Video Findings:</b></p> <p style="text-align: right;">1</p>	<p style="text-align: center;"><u>Narendra JANA (21089233), DOB 27/10/1984, Investigation of 18/09/2019</u></p> <p>No clinical events were captured on video.</p> <p>ECG: ECG (Lead I) shows a regular rhythm of 76-80 bpm. QTc = 0.39s.</p> <p><u>Ms B. Colla</u> <u>Clinical Physiologist</u></p> <p><u>Dr H. Mar</u> <u>Specialist Registrar in Clinical Neurophysiology</u></p> <p><u>Dr S. O'Sullivan</u> <u>Consultant in Clinical Neurophysiology</u></p> <p>This report has been electronically approved.</p> <p style="text-align: right;">2</p>
--	---

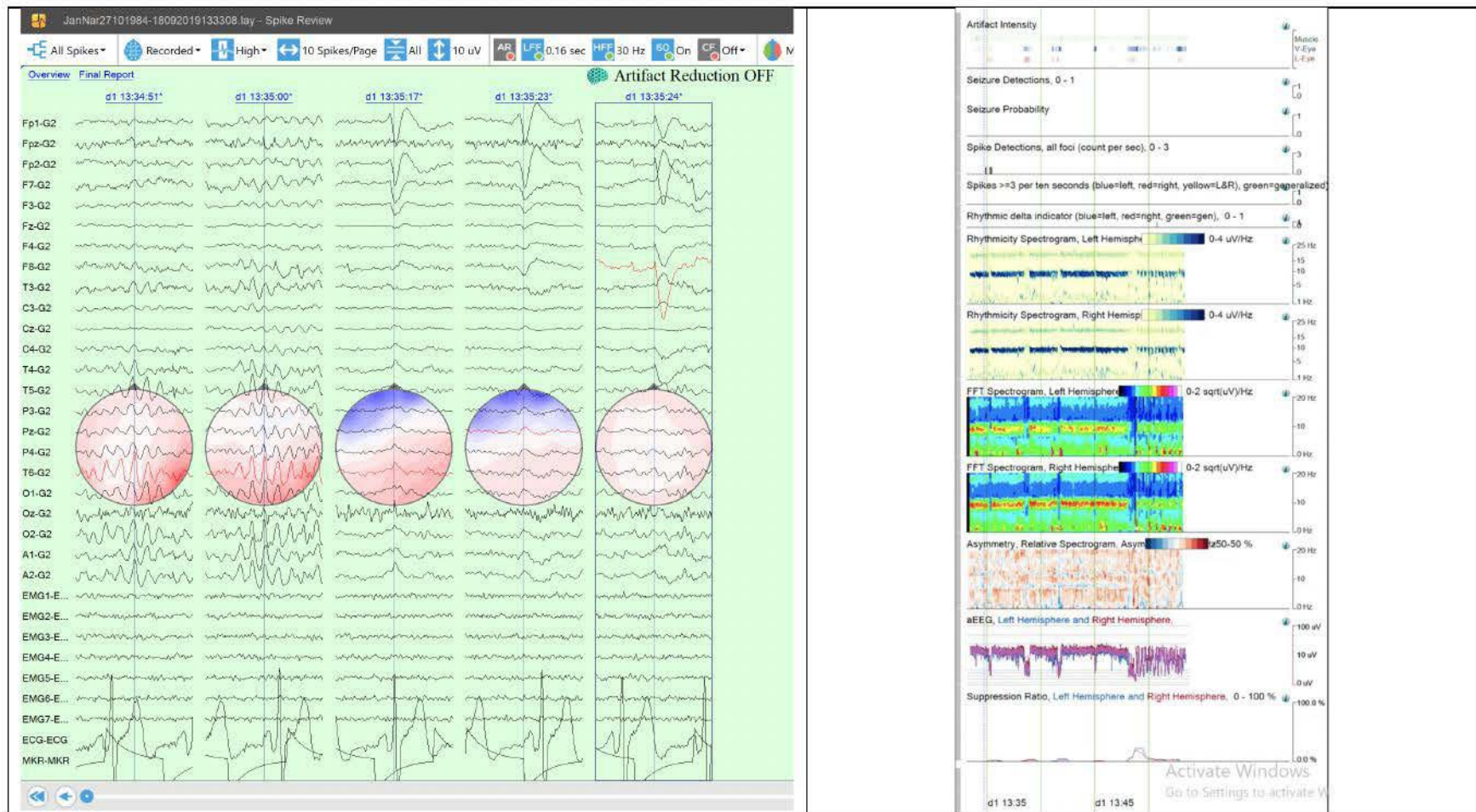
There may no beta activity in the EEG. The diagnostician was trying to have a sense of humor in stating “bet an act”.

EEG shows a few spike waves but no seizures, which is indicative of the interictal phase of a seizures. Epileptics are interictal 99 % of the time.

This is similar to former EEGs that show interictal effects or full seizures. The EEG shows a few spike but no seizures.

### Appendix:

All recorded spikes:





Dr. Sidhu's report:

**CONFIDENTIAL**  
Patient Name: JANA, Narendra

4/11/2019 Pg. 2  
1014595130

**NHS**  
**University College London Hospitals**  
NHS Foundation Trust

QUEEN SQUARE CAMPUS  
QSC M1506  
Queen Square  
London  
England  
WC1N 3BG  
Neurology - Epilepsy General

5 November 2019

**Private and Confidential**  
LANCASTER GATE MEDICAL CENTRE  
Lancaster Medical Centre  
20-21 Leinster Terrace  
London  
W2 3ET  
VIA DocMan

Patient demographics		Attendance details	
Patient name	Mr. Narendra JANA	Date of contact	30/10/2019
Date of birth	27/10/1984	Consultation method	Clinic/Practice Visit
Gender	male	Seen by	Aravindhan Baheerathan
NHS number	721 602 5954	Responsible health care professional	Meneka Sidhu, Consultant Doctor
Hospital ID	21089233	Outcome of attendance	Active Monitoring (new/further treatment not required at this point) [35]
Patient address	[REDACTED]	GP practice	
Telephone no.	There is no home phone number on file. [REDACTED]	GP practice identifier	E87722
		GP name	Unnamed General Practitioner
		GP details	LANCASTER GATE MEDICAL CENTRE LANCASTER MEDICAL CENTRE 20-21 LEINSTER TERRACE LONDON W2 3ET 020 74799750

**uclh**  
UCLH is an NHS Foundation Trust comprising: University College Hospital (incorporating the Blizard, Barrett Anderson Wing, the Macmillan Cancer Centre and University College Hospital at Westmead); Queen's; Royal London Hospital for Integrated Medicine; Royal National ENT and Sore throat Hospital; National Hospital for Neurology and Neurosurgery at Queen Square and Cleveland Street; Institute of Sport, Exercise and Health; Hospital for Tropical Diseases.

**CONFIDENTIAL**  
Patient Name: JANA, Narendra

4/11/2019 Pg. 3  
1014595130

Dear LANCASTER GATE MEDICAL CENTRE,

It was a pleasure to see Mr Jana in the Epilepsy clinic. He has been reviewed and referred by Dr Trip (Consultant Neurologist) for neurological symptoms that has been diagnosed elsewhere as "multiple sclerosis" for which he has received numerous disease modifying treatments. His history with regards to his other neurological symptomatology is well documented in Dr Trip's letter. He has been referred here for long-standing paroxysmal attacks that have been occurring which have been diagnosed as "Epilepsy" elsewhere.

He is a 35 year old, right handed gentleman that started to have unpleasant sensory symptoms in 2008. 12 months later, he started to have what he described as "absence attacks". What he describes is a "smell of something bad" which acts as an aura. This is followed by a dialeptic event where he loses awareness (no automotor activity is noted) for a few minutes and is followed by a dyscognitive state which lasts 20-40 minutes. During the dyscognitive state, he is unable to speak to people but is able to follow commands. He is then confused for around 20 minutes. These events occur around twice a day at present and can be triggered by eating, over-exertion and lack of sleep. He has never suffered a generalised tonic clonic seizure. They used to occur much more frequently- around 15X per day.

He has been diagnosed as "focal epilepsy" elsewhere and has had a trial of multiple anti-epileptic drugs including Levetiracetam (which resulted in a "pseudo-bulbar affect"), Carbamazepine (which resulted in a withdrawal effect), Gabapentin (no benefit) and Sodium Valproate (which resulted in a withdrawal effect). He feels his seizures have been better since his MS has improved and he feels that what has helped this has been the combination of rituximab, iron chelation and Simvastatin. He is currently not on any anti-epileptic drugs. He takes Simvastatin 80mg Nocte.

He has had an EEG (organised by Dr Trip) which has been reported as normal with no epileptiform or inter-ictal activity. He also enquired about obtaining his EEG wave form which having discussed with our neurophysiology team is not something we routinely do.

He is a non-smoker, does not drive and does not drink alcohol. He lives alone and is currently seeking asylum to the United Kingdom.

At this moment in time, it is important that we gain clarity as to the underlying neurological diagnosis. He is having paroxysmal dyscognitive events and has a completely normal EEG. A MRI and Lumbar Puncture is pending.

Based on these and how these events progress over the next 6 months, we can make a decision as to how to proceed with regards to investigation of these events.

Yours Sincerely,

*Electronically checked & signed*

**Aravindhan Baheerathan**  
Specialist registrar in Neurology  
Consultant: Dr M Sidhu