

2012 October 30th and December, 27th 2012

- Dr. Georgia Montouris - Boston Medical Center – Boston, MA
 - Criminal Fraud →

(Boston Medical Center Neurology)

Dr. Georgia Montouris

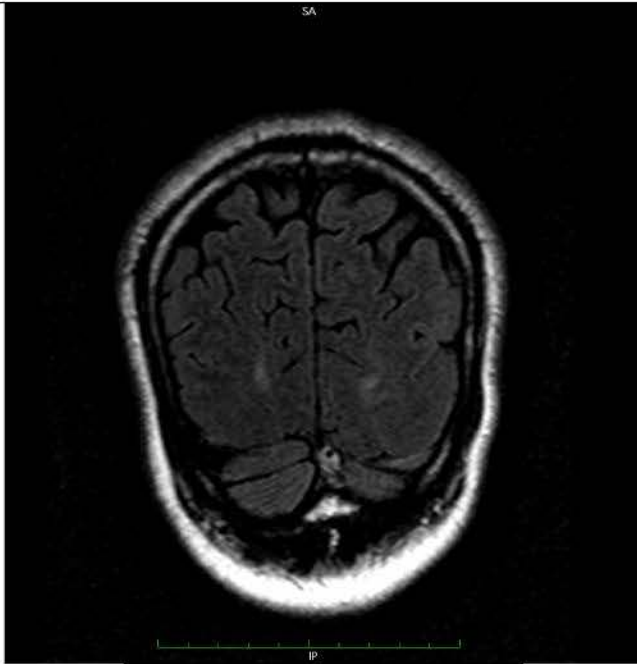
Fraudulated Radiology Report to Try and Hide the Prevalence of Neurological Damage

The next evidence of fraud to further negligence in a medical setting takes place in December, 27th 2012.

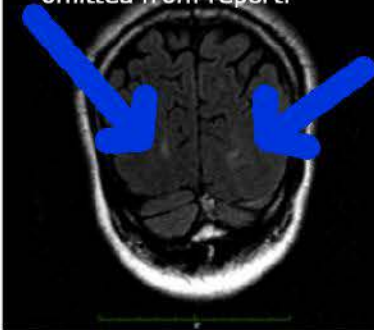
This MRI shows a prominent feature in the MRI series (which causes a type of blindness derived from by a combination of inflammation over the optic nerve and directly in the visual processing center of the brain, the occipital lobe). Radiologist intentionally fails to mention the large feature of neuroinflammation in the radiologist report:

<p>BU Neurology - Shapiro Center Boston Medical Center 725 Albany Street, Suite 7B Boston, MA 02118 Phone: 617-638-8456 Fax: 617-638-8466</p> <p>Date Printed: November 2, 2012</p> <p>Page 1 Chart Document</p> <p>NARENDRA JANA MRN: 3859615</p> <p>10/27/2012 - Radiology Result: MRI BRAIN WITHOUT CONTRAST Provider: Georgia Montouris MD (2988) Location of Care: Boston Medical Center</p> <p>Patient: NARENDRA JANA Note: All result statuses are Final unless otherwise noted.</p> <p>Tests: (1) MRI BRAIN WITHOUT CONTRAST (MB) MRI BRAIN WITHOUT CONTRAST SEE REPORT *** Final Report ***</p> <p>BOSTON MEDICAL CENTER DEPARTMENT OF RADIOLOGY</p> <p>Patient Name: JANA, NARENDRA MRN No.: 3859615 DOB: 10/27/1984</p> <p>Patient Location: H MRI Ordering MD: MONTOURIS, GEORGIA M.D. Date: 10/27/2012 11:07 AM Examination: MRI BRAIN WITHOUT CONTRAST Exam Number: 20279941</p> <p>EXAMINATION: MRI BRAIN WITHOUT CONTRAST</p> <p>HISTORY: Seizures</p> <p>COMPARISON: None</p> <p>TECHNIQUE: Sagittal T1, axial T1, T2 GRASE, FLAIR, gradient echo, and diffusion imaging sequences were obtained of the brain. High resolution coronal IRTSE and FLAIR images were obtained.</p> <p>FINDINGS: No acute infarct, hemorrhage, or mass. There are no areas of brain parenchymal signal abnormality. The ventricles, cisterns, sulci are not effaced. No hydrocephalus or midline shift. The major flow voids in the anterior-posterior circulation and dural venous sinuses are preserved.</p> <p>No neural migrational disorder. No mesial temporal sclerosis.</p> <p>The orbits are unremarkable. The paranasal sinuses and mastoid air</p>	<p>BU Neurology - Shapiro Center Boston Medical Center 725 Albany Street, Suite 7B Boston, MA 02118 Phone: 617-638-8456 Fax: 617-638-8466</p> <p>Date Printed: November 2, 2012</p> <p>Page 2 Chart Document</p> <p>NARENDRA JANA MRN: 3859615</p> <p>cells are clear.</p> <p>IMPRESSION: Unremarkable brain MRI.</p> <p>Dictated By: JIMMY NANG, M.D. Date: 10/29/2012 11:44 AM Electronically Signed By: JIMMY NANG, M.D. Date: 10/29/2012 11:44 AM</p> <p>Note: An exclamation mark (!) indicates a result that was not dispersed into the document. Document Creation Date: 10/29/2012 11:44 AM</p> <p>(1) Order result status: Final Collection or observation date-time: 10/27/2012 11:07:00 Requested date-time: Receipt date-time: Reported date-time: Referring Physician: Ordering Physician: GEORGIA MONTOURIS (GEORNT00) Specimen Source: Source: RAD Filler Order Number: 20279941MB Lab site:</p> <p>Filed automatically (without signature) on 10/29/2012 at 11:44 AM</p> <p>Narendra Jana</p> <p>Radiological report states "flair images were taken", but doesn't mention the neurological damage caused by MS.</p>
---	--

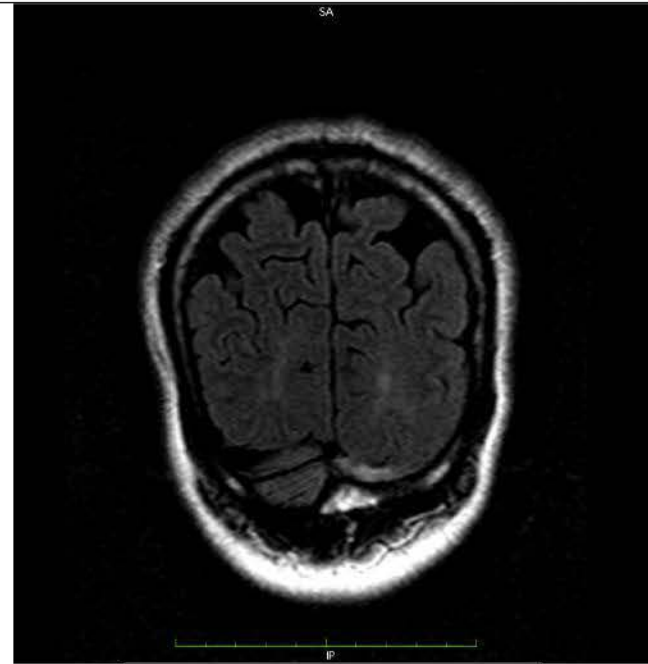
Narendra
Jana



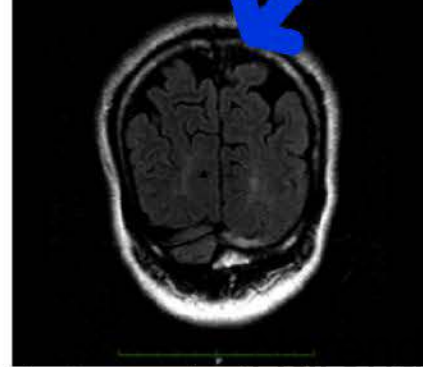
Brain lesions intentionally
omitted from report.



The two white patches in the brain MRI are signs of neuroinflammation also known as “lesions” in a MRI. Or areas of neurological damage.



Posterior brain cerebral atrophy omitted
from report.



There is atrophy in the posterior (back) part of the brain as well.
The atrophy is due to medical negligence.

Both the neurologist and epileptologist can clearly see the features because its extremely prominent in the MRI and seen in later studies as well.

The radiological report glibly states “flair images were taken” but fails to mention the large feature of neuroinflammation in the MRI series; this is intentional to avoid medical diagnosis of multiple sclerosis to withhold treatment. The radiologist also fails to mention the clear feature of premature atrophy in the posterior part of the brain as well (this happens to people in their 50s not 20s). The long term mistreatment has already caused a massive amounts of neurological damage by 2012, that’s 4 years of mistreatment causing harm to my brain and what is eventually shown in spine as well. In the process to neurodegeneration I have collectively had thousands of seizures on a daily basis leaving be bedridden for almost 4 years then and intermittently unable to move due to MS. I was also intentionally isolated form my peers for this period of time as well so there were no social checks to prevent the medical negligence from happening.

The next report is related to this report.

Narendra
Jana