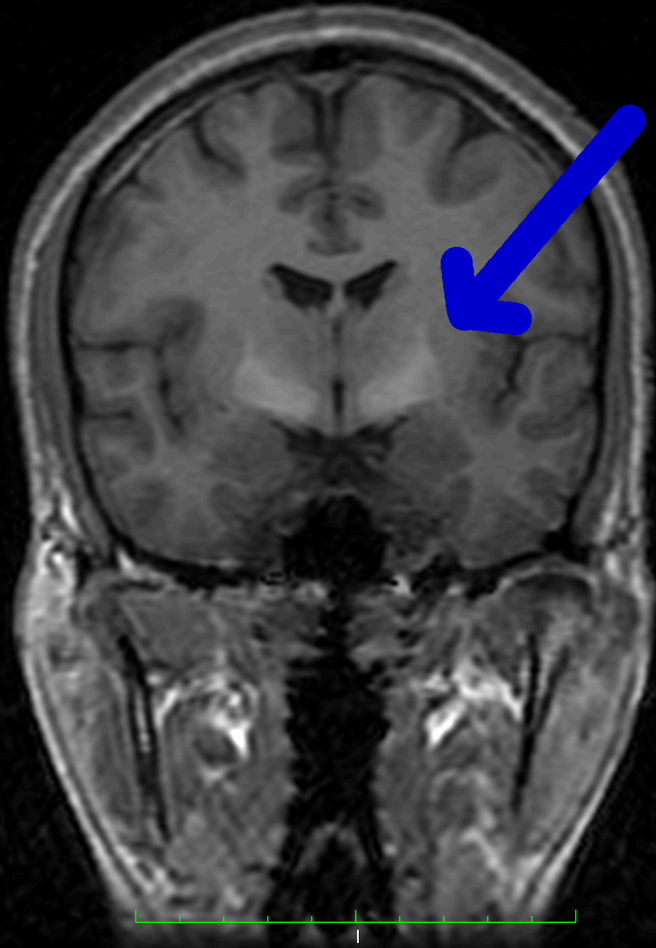




Image size: 256 x 256
View size: 3138 x 1682
WL: 112 WW: 224
X: -55 px Y: 207 px Value: 0.00
X: -172.12 mm Y: -4.00 mm Z: -62.03 mm



Brain MRI done in 12/18/2008:

Large feature of inflammation in the basal part of the brain, bilaterally (both sides of brain). It's a gross feature typical of medical toxicology (manganese metal toxicity). Medical negligence under neurology and toxicology eventually caused gross brain and neuro spinal degeneration, with progressive multiple sclerosis (MS).

The medical negligence was later found to be intentional.

Zoom: 657% Angle: 0
Im: 27/48 (P -> A)
Uncompressed
Thickness: 3.50 mm Location: -4.00 mm

TE: 5 TR: 35
FS: 15000
12/18/08, 2:22:50 PM
Made In Horos