

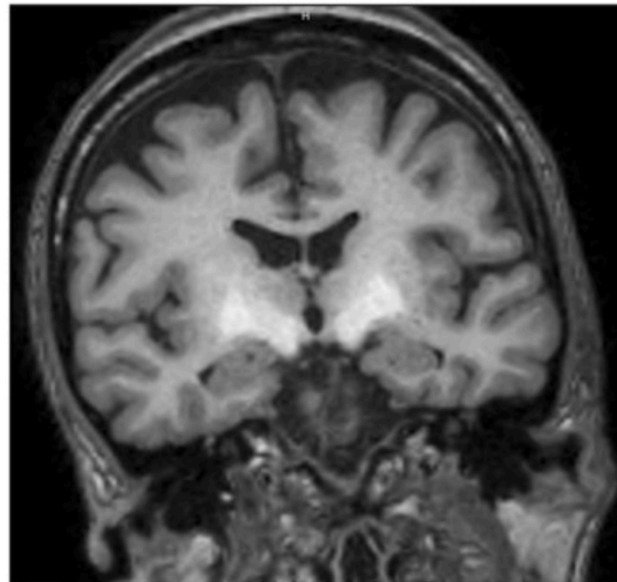
PMC full text: [Orphanet J Rare Dis. 2017; 12: 92.](#)

Published online 2017 May 18. doi: [10.1186/s13023-017-0632-2](#)

► [Copyright/License](#) [Request permission to reuse](#)


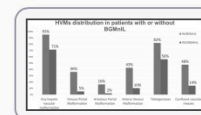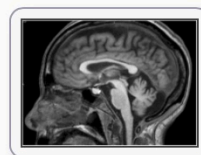
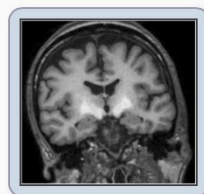
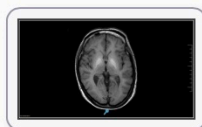
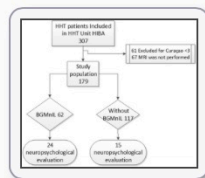
<< Prev Fig. 3 Next >>

Fig. 3



BG-MnIL MRI image. T1 sequence Brain MRI showing hyperintensity signal in the basal ganglia as consequence of manganese deposition

Images in this article



Click on the image to see a larger version.