

Late 2008 and Early 2009

2008 December 18th

- **Dr. Evan Murray - Belmont, Massachusetts, USA**
- **Criminal Negligence →**

Gross features of multiple sclerosis (neuroinflammation) present by December of 2008 and the medical images from the medical tests are ignored:

The neuroinflammation is due to medical toxicology, namely a manganese metal toxicity. Under toxicology it's a gross finding.

The first MRI was taken in December, 18th, 2008:

There is a very large intensity in the basal part of the brain.

People with these features in a MRI are required to have intensive diagnostics (lumbar punctures and blood tests) along with intensive care for the underlying clinical condition (neurotoxicology that results in multiple sclerosis) in a hospital setting.

It's like finding a large brain tumor in a patient and not acknowledging it and refusing to treat it. Nothing is done then, leaving the patient (me) in excruciating physical pain with no medical treatment for a decade with repeated attempts at asking for medical help (a time line of events is given), there were three different toxicologists in three hospitals (UMass Memorial, Mass General, and Beth Israel in Massachusetts) that were consulted and all refused to give the required detoxification treatment (IV medications with dialysis and plasmapheresis).

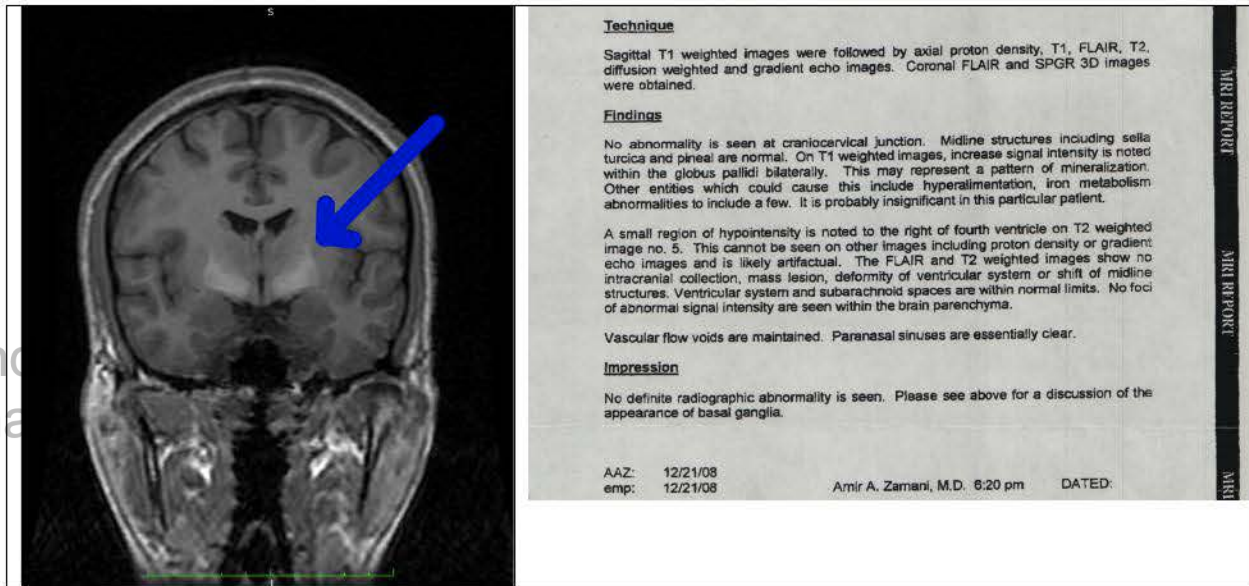
It was later determined that the medical negligence was intentional with intent to cause harm (thus causing a need for asylum). Meaning it was negligence with the intent for causing physical disfigurement or physical disability (immobility).

In the MRI below, the white intensity means a large part of the brain is inflamed.

The neurologist is required to give a specific selection of medications to reduce neuroinflammation along with dialysis or plasmapheresis to prevent neurological damage. It could be likened to a brain tumor that is ignored and it's atypical to see these features in an MRI series.

Narendra
Jana

Narendra
Jana



Narend
Jana

It is illegal in medicine to not do further testing and to ignore features of gross presentation (malice in a medical setting). It invariably means the patient will have a neurodegenerative syndrome and that it will effect the person's brain and spinal column warranting an immediate need for medications to stop the disease process.

Without medications the condition predictably caused neurodegeneration of both the brain and the spinal column, which is apparent in future MRI series images. The condition is secondary progressive multiple sclerosis (MS).

In order to hide the effects from negligence future radiology reports are falsified or the radiologist is instructed to erase images that show disease pathology and progression.

Dr. Evan Murray is the clear ethology (origin) of criminal negligence and fraud supported by other doctors during that time period (Dr. Richard Falzone being the prime suspect).

Narendra
Jana