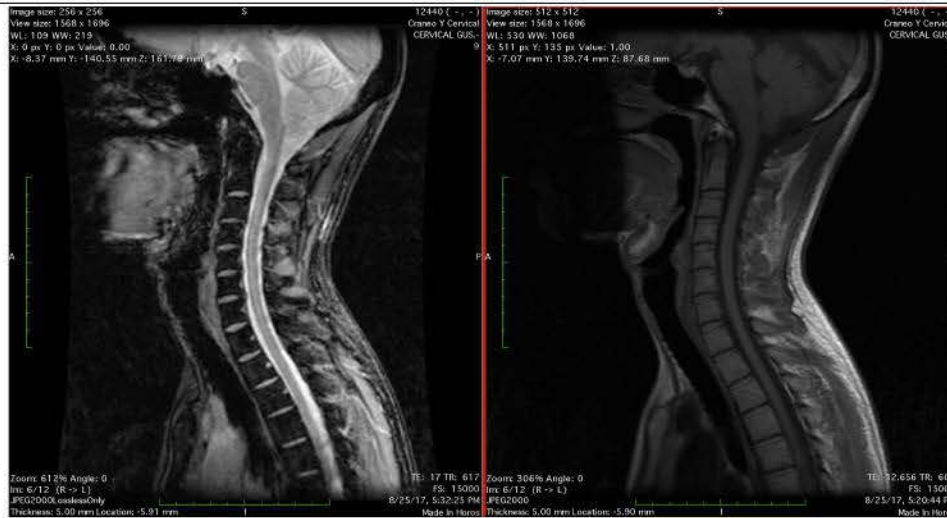

## 2017 September 27<sup>th</sup> ER Appointment in Mexico City – Hospital Angeles

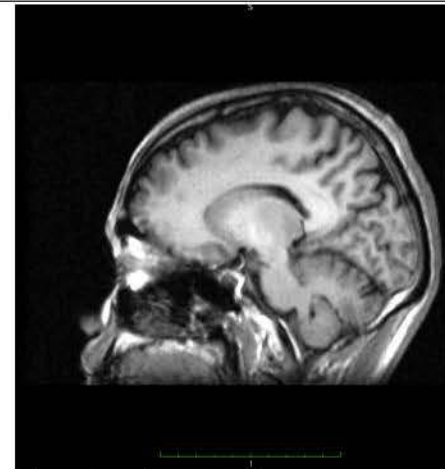
With the doctors denying treatment in the US for a clear medical emergency, I flew to Mexico City Mexico where in a late night appointment after an earthquake in the center of Mexico City I had my first ER where an effective medication for MS was given.

The condition was severe and clearly required medical treatment.

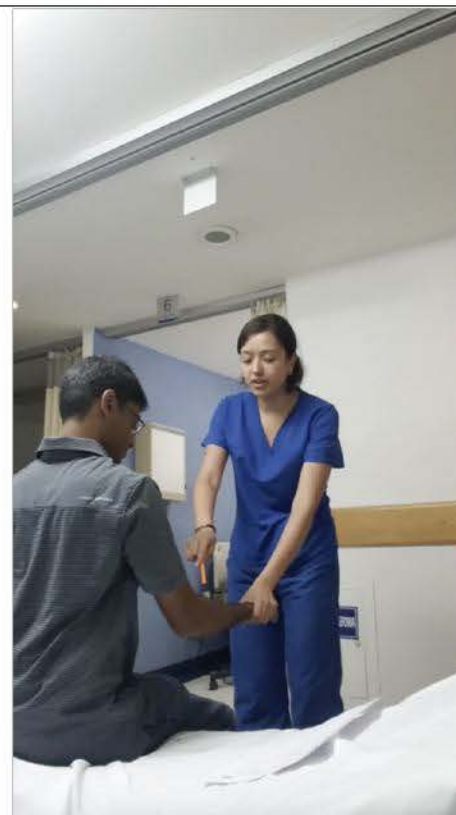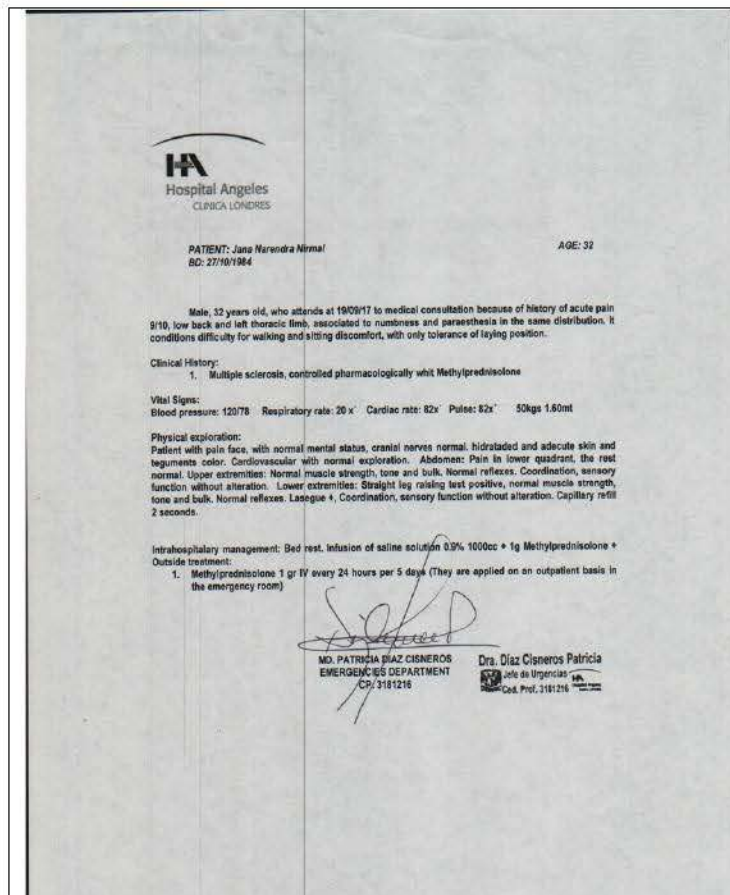
The MRI before the ER showed gross lesions in the brain and cervical spine with contrast enhancement requiring immediate treatment.



The MRI needs to be viewed in a computer, its very clear.

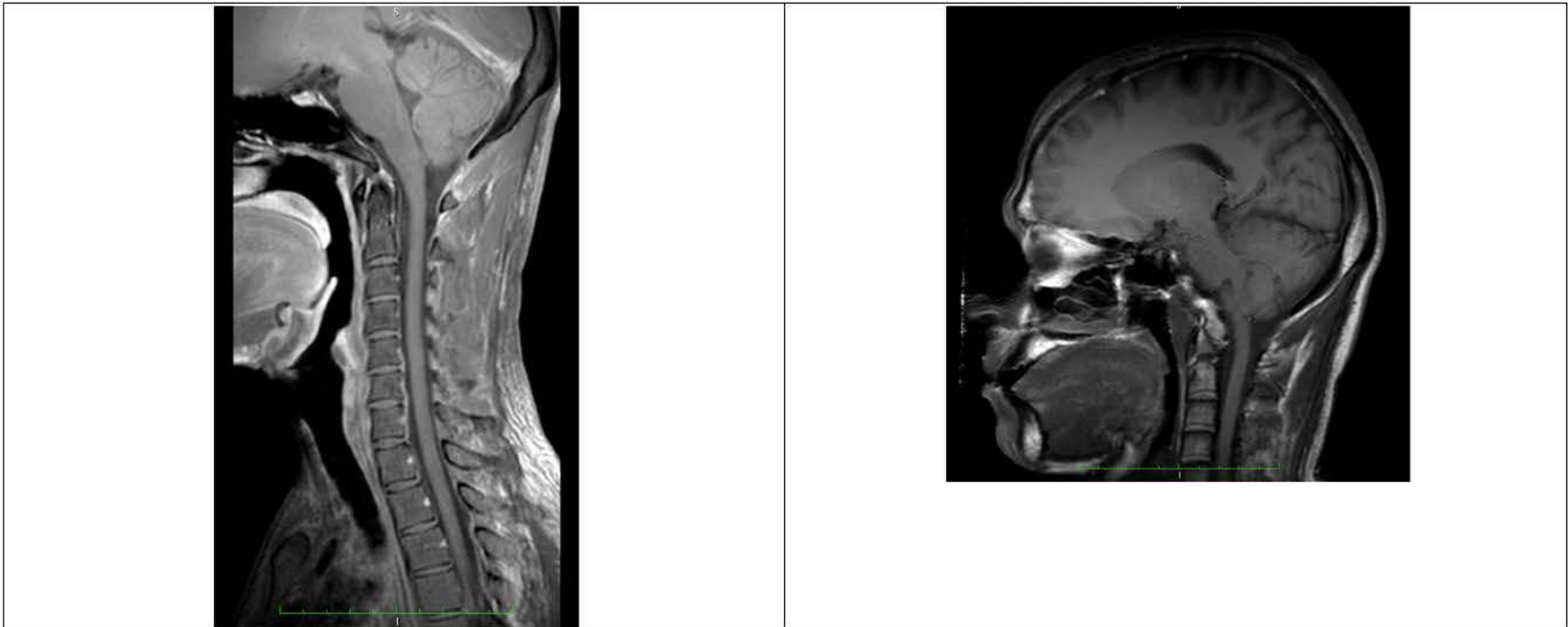


There is a large inflammatory T1 lesion extending from the basal brain down to the upper cervical spine requiring emergency treatment ignored in the US.



The response from the medication is immediate and there is a temporary recovery from the condition. Optic neuropathy diminishes and physical pain and mobility improve, things get better for a period of 1 to 2 months, which is typical for people who have a secondary progressive form of MS. (the treatment gives the CNS a break from auto immune reactions but in secondary progressive forms of MS the effect is temporary).

Another MRI is done immediately afterwards in Mexico City on September 25<sup>th</sup>, 2017 to show the clinical improvement from medications. It looks better, the huge white regions of T1 inflammation have diminished due to the medications:



But these effects only last a few weeks (maybe 2 to 4 weeks) and then it's a full relapse.