

## 2015 December to February 2016

- Dr. Vladan Milosavljevic - New England Neurological Associates – Lawrence, Massachusetts
  - Criminal Fraud and Negligence →
- Dr. Maosong Qi
  - Possible Fraud →
    - Possible fraud in blood tests

### Dr. Vladan P. Milsavljevic:

A number of tests are ordered by Dr. Vladan P. Milsavljevic in New England Neurological associates.

Three different tests are done: A MRI, a EEG, and EMG. The MRI, EEG, and EMG results are either hidden, fraudulated, or falsified.  
MRI:

Documents DB													
Albums	Patient name	Report	Lock	Patient ID	Age	Accession...	Study Description	Modality	ID	Comments	Status	Date Acquired	Jana Narendra Nirmal Mr.
Database 24	▼ Jana Narendra		—	4505040	34/31 y	450...40.1	Mri Brain	MR	24753			12/3/15, 10:5	Brain (Mri + Mra + Mrv) MR
8 Cases with comments	3-pl T2* FGRE						BRAIN 8 CH-1	MR	1			12/3/15, 10:5	3/12/16 1 image
0 Interesting Cases	Calibration Scan						BRAIN 8 CH-2	MR	2			12/3/15, 10:5	
0 Just Acquired (last hour)	*T1-Sagittal						BRAIN 8 CH-3	MR	3			12/3/15, 10:5	
0 Just Added (last hour)	T2-Ax FSE						BRAIN 8 CH-5	MR	4			12/3/15, 10:5	
0 Just Opened	Ax DWI 1000b						BRAIN 8 CH-4	MR	5			12/3/15, 11:0	
0 Today CR	Ax T2 FLAIR						BRAIN 8 CH-6	MR	6			12/3/15, 11:0	
0 Today CT	IRON Axial GRE						BRAIN 8 CH-7	MR	7			12/3/15, 11:0	
	Apparent Diffusion Coefficient (mm <sup>2</sup> -s)						BRAIN 8 CH-4	MR	500			12/3/15, 11:0	
Sources	▼ Jana Narendra Nirmal Mr.		—	102536440	34/31 y	BM...3838	Brain (Mri + Mra + Mrv)	MR	11559			3/12/16, 4:1	
Documents DB	▼ Nirmal Narende		—	271084-10000	34/32 y		Head	MR	2929			1/10/17, 8:5	
Horos_201902...832_c5u0z DB	3Plane Loc SSFSE						. Head	MR	1			1/10/17, 2:56	
Horos_201902...32_68kE2k DB	Ax T2 FSE						. Head	MR	2			1/10/17, 2:56	
Horos_201902...32_tahWem DB	Ax T2 FLAIR						. Head	MR	3			1/10/17, 2:56	
Horos_201902...32_SSbCFb DB	Ax T1 3D FSPGR						. Head	MR	5			1/10/17, 3:02	
Horos_201903...36_jbCyda DB	Cor T2 FLAIR						. Head	MR	6			1/10/17, 3:05	
Horos_201904...6_mXuk0s DB	Ax DWI						. Head	MR	7			1/10/17, 3:06	
Horos_201904...056_Jux5s6 DB	Cor T2 FSE FS						. Head	MR	8			1/10/17, 3:13	
	3D SWI						. Head	MR	9			1/10/17, 3:16	
Activity	AxT1 FSPGR						. Head	MR	500			1/10/17, 3:02	
	Sag T1 FSPGR						. Head	MR	501			1/10/17, 3:02	
	CorT1 FSPGR						. Head	MR	502			1/10/17, 3:02	
	Apparent Diffusion Coefficient (mm <sup>2</sup> -s)						. Head	MR	700			1/10/17, 3:06	
	FILT_PHA: 3D SWI						. Head	MR	900			1/10/17, 3:16	
	SWI MinIp						. Head	MR	901			1/10/17, 3:16	
	▼ Nirmal Narende		—	27101984	34/32 y		C-Spine	MR	2930			1/10/17, 9:2	
	3Plane Loc SSFSE						. Spine	MR	5			1/10/17, 9:2	

The December 2015 MRI series has missing series and images (its an incomplete MRI series that isn't useful for medical diagnostics). The technician may have erased some planes to support the subsequently falsified report (typical pattern of criminal fraud in the US). So the MRI and report was fraudulated.  
The January 2017 brain MRI is given for comparison of how many planes and images there should be in an MRI.

The report is given below:

**MRI BRAIN Results Report**

Pt Name:	Jana, Narendra	MRN:	726305
Pt ID:	2015011914	Acct No:	7021006908
DOB:	10/27/1964	Age/Sex:	34Y/M
Adm DTime:	12/03/2015 05:46	Atn Dr:	
Nurs Sta:	MRI LH	Rm & Bed:	
Dx:			
Alrg:	Not Assessed		

Order Name:	MRI BRAIN (1212)	Observation DTime:	12/03/2015 17:01
Result Name:	MRI BRAIN	Result Status:	Final Result

\*\*\*Final Report\*\*\*

DATE OF EXAM: Dec 3 2015

LHR 1212 - MRI BRAIN : CPT:

RESULT:

CLINICAL HISTORY: Confusion. Memory loss.

TECHNIQUE: Sagittal T1, Axial T2, FLAIR, diffusion, and gradient echo images of the brain obtained.

COMPARISON: None.

FINDINGS: The ventricles, sulci and extra-axial CSF spaces are within normal limits.

There is no acute infarct.

There is no intracranial mass.

There is no evidence of hemorrhage.

There is mild mucosal thickening in the left maxillary sinus.

IMPRESSION: Unremarkable MRI of the brain.

Interpreting Physician: RODRICK WILLIAMS MD  
Transcribed by / Date: tab RM on Dec 4 2015 7:10A  
Approved Electronically by / Date: tab WILLIAMS, RODRICK MD Dec 4 2015 7:10A

**Comments**

Result Comments:

Requisition Comments:

Pt Name:	Jana, Narendra	MRN:	726305	MRI BRAIN Results Report
Rm/ Bed:				ORE_0126.rpt v1.00
				Page 1 of 2
Copyright © Cerner Health Services, Inc. All rights reserved.				Printed By : Davis, Nakaysha
Crystal Reports © 2019 Business Objects SA. All rights reserved.				Printed On: 08-Apr-19 09:30

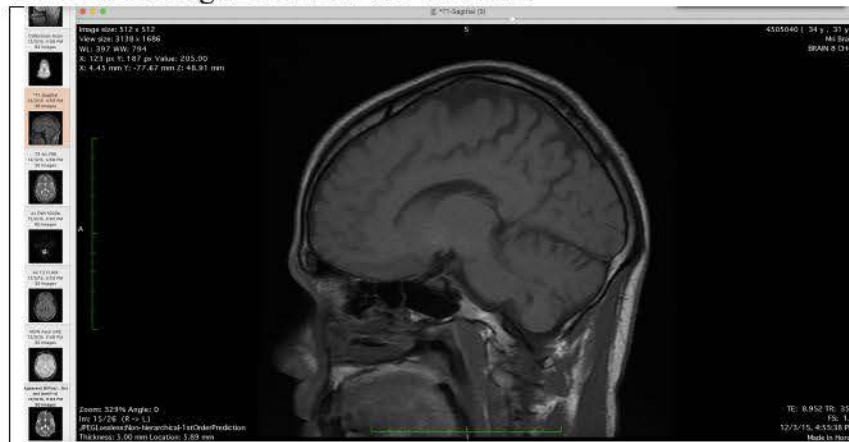**MRI BRAIN Results Report**

Pt Name:	Jana, Narendra	MRN:	726305
Pt ID:	2015011914	Acct No:	7021006908
DOB:	10/27/1964	Age/Sex:	34Y/M
Adm DTime:	12/03/2015 05:46	Atn Dr:	
Nurs Sta:	MRI LH	Rm & Bed:	
Dx:			
Alrg:	Not Assessed		

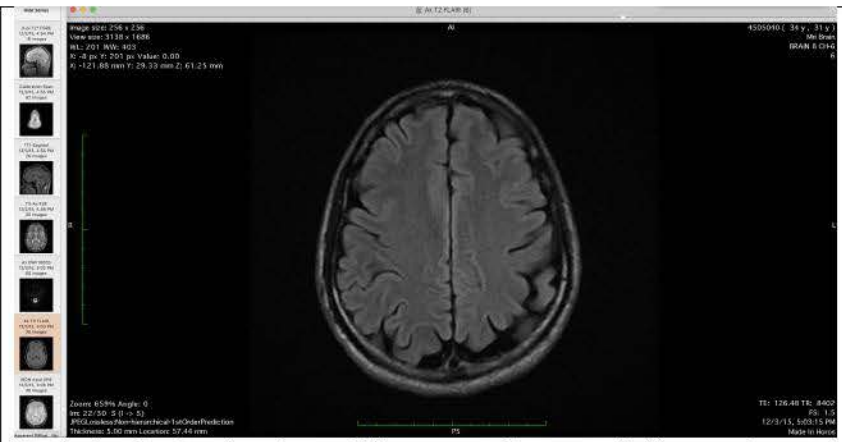
Ordering Dr:	000183	Order Date/Time:	12/03/2015 15:27
		Ord# / Occurrence#:	15663314 / 25880361

Pt Name:	Jana, Narendra	MRN:	726305	MRI BRAIN Results Report
Rm/ Bed:				ORE_0126.rpt v1.00
				Page 2 of 2
Copyright © Cerner Health Services, Inc. All rights reserved.				Printed By : Davis, Nakaysha
Crystal Reports © 2019 Business Objects SA. All rights reserved.				Printed On: 08-Apr-19 09:30

The outstanding features in this MRI are:



A bilateral inflammation of the Basal Ganglia.



Posterior brain atrophy and there may be some inflammatory lesions around the ventricles of the brain.

For the electromyography (EMG) it could not be determined if the values for the EMG were intentionally hidden or not. But considering that there is significant amount of damage to the upper cervical column by that point in time its easy to determined that there would be neuropathy resulting from cervical lesions. I believe the doctor wrote the report with the hopes that a MRI of the spinal column would not be done.

Some of the values are hidden in the report and it maybe intentionally.

## EMG:

NEW ENGLAND NEUROLOGICAL ASSOCIATES  
ELECTROMYOGRAPH / NERVE CONDUCTION STUDY

Name: Narendra Jana  
Date: 2/1/16  
Ordering M.D.: Dr. Mulo  
Performing M.D.: Dr. Mulo

	Right			Left		
	LATENCY	AMP	VELOCITY	LATENCY	AMP	VELOCITY
	ms	uv/mv	m/sec	ms	uv/mv	m/sec
<b>Upper Extremity Nerve:</b>						
Radial sensory						
Median sensory						
Ulnar sensory						
Median Motor:						
	Wrist					
	Elbow					
	ERB's					
Median F-Wave						
Ulnar F-Wave						
Ulnar Motor:						
	Wrist					
	Below Elbow					
	Above Elbow					
	ERB					
Radial Motor:						
	Elbow					
	Proximal					
	ERB					
<b>Other: Transcarpal</b>						
	Median					
	Ulnar					
<b>Facial Nerve:</b>						
Orbicularis Oculi						
Nasalis						
Orbicularis Oris						
<b>Lower Extremity:</b>						
Sural sensory						
Peroneal Motor:						
	Ankle	4.0	2.7	3.1	1.4	
	Below fibular head	10.2	2.6	5.0	2.0	5.0
	Above fibular head					
Peroneal F-Wave						
Posterior Tibial F-Wave						
Posterior Tibial Motor		4.2	5.0	4.6	4.0	
Medial Plantar						
	Lateral Plantar					
	Popliteal Fossa					
H-Reflex: Gastroc/Soleus						
H-Reflex: Other						
Femoral:						
	Distal					
	Proximal 1					
	Proximal 2					
Other:	Sup. Peroneal			2.4	1.2	
NR = No response						
TD = Technical Difficulty						

*Handwritten notes:*  
"briova" (with arrow pointing to ERB section)  
"Kristen B." (with arrow pointing to Sup. Peroneal section)

The sticky note occludes some diagnostic values in the test. Im not sure if its intentional.



Riverwalk  
354 Merrimack Street  
Lawrence, MA 01843  
(978) 687-2321  
Protected Health Information Fax: (978) 722-7287  
www.neneuro.com

Division of Neurological Surgery  
Howard M. Gussner, M.D., F.A.C.S.  
Founder / Medical Director  
Peter J. Gills, M.D., F.A.C.S.  
William P. McCann, M.D., F.A.C.S.  
Bruce R. Cook, M.D., F.A.C.S.  
Henry T. Li, M.D., F.A.C.S.  
K. Subashini Kandas, M.D., F.R.C.S.  
Katherine Crank, M.D., Ph.D.  
Frankie D. Sorey, P.A.-C.  
David R. Nevicki, P.A.-C.

Division of Orthopedic Spine Surgery  
Joseph E. Pinterofsky, M.D.

Division of Neurology  
Jonathan S. Marav, M.D.  
Neurology/Epileptology  
Jonathan Ross, M.D.  
Aron Farkashaus, M.D.  
Lenny Y. Xue, M.D., Ph.D.

Neurology/Neurovascular Disorders  
Jennifer Collins, M.D.  
Min Zhu, M.D., Ph.D.

Neurology/Movement Disorders  
Shabbir A. Abbasi, M.D., MRCP (UK)

Neurology/Neuro-Oncology  
Vladan P. Milsavijevic, M.D.

Neurology/Vascular Neurology  
Andrew P. Schoen, M.D.  
Jason C. Harris, M.D., Ph.D.

Division of Pediatric Neurology  
Neurology/Clinical Neurophysiology  
Myra J. Oren, M.D.

Division of Rheumatology  
Monique Qi, M.D., Ph.D.

Division of Physical Medicine & Rehabilitation  
Physiatry  
Ricardo P. Espandung, M.D.  
Srinivasan R. Padmanabhan, M.D.  
Scott R. Masterson, M.D., CME  
Thomas P. Leah, M.D.

Physiatry/Musculoskeletal Medicine  
Salim M. Mahmood, M.D.

Physiatry/Interventional Medicine  
Jon Macer, M.D., MPH

Division of Pain Medicine  
Anesthesiology  
Jeffrey A. Nelson, M.D.  
Michael C. Connolly, M.D.  
Richard E. Blyskal, M.D.  
Karen N. Ngole, P.A.-C.

Division of Neuro-Behavioral Medicine  
Psychiatry  
Marc M. Sadowsky, M.D.

Psychology  
Robert A. Moxerman, Ph.D.

Administration  
Joan T. Fancher  
Administrator/CEO

Serving New England Since 1969

10 George Street, Suite 300  
Lowell, MA 01852  
(978) 438-1401

One Parkway  
Haverhill, MA 01830  
(978) 373-4773

21 Highland Avenue  
Newburyport, MA 01850  
(978) 455-1033

Medical Arts Building  
148 Conant Street  
Nashua, NH 03081  
(603) 882-2114

West Campus  
29 Northwest Blvd.  
Nashua, NH 03063  
(603) 578-9770

198 Littleton Road  
Suite 303  
Winifred, MA 01886  
(978) 377-1790

## EMG REPORT

NAME: NARENDRA JANA

DOB: 10/27/1984

DATE OF STUDY: 02/01/2016

REASON FOR STUDY: Bilateral leg numbness and pain.

## SUMMARY OF THE STUDY

Bilateral peroneal and posterior tibial compound muscle action potential amplitudes are normal with normal distal latencies and normal peroneal conduction velocities. Bilateral "H" responses are absent. Bilateral sural and left superficial peroneal sensory nerve action potential amplitudes are normal with normal distal latencies.

On needle examination, decreased activation was seen in bilateral VL, PL, AH and right AT muscle. No active denervation or chronic reinnervation changes were seen in other tested muscles including left AT and bilateral medial gastrocs.

IMPRESSION: Normal study.

Vladan P. Milsavijevic, M.D.


msg/t: 2/4/2016 Copy retained for our files.

This may not be a "normal" study. There are cervical lesions and cervical spine atrophy.

But the EEG (done on 01.06.2016) and the report for the EEG is easy to determine as being fraudulated since another EEG was done a little more than 2 months later on March 16<sup>th</sup> and then a second time on May 4<sup>th</sup> of 2017 (both of which show either features of epilepsy or seizures). EEGs don't change that quickly especially in long standing conditions. The clinic that did the EEG (New



England Neurological Associates) is required to keep diagnostic tests for a period of a decade but refused to rescind the actual EEG data.



Riverwalk  
354 Merrimack Street  
Lawrence, MA 01843  
(978) 687-2321  
Protected Health Information Fax: (978) 722-7287  
[www.neneuro.com](http://www.neneuro.com)

Division of Neurological Surgery  
Howard M. Gardner, M.D., F.A.C.S.  
Founder / Medical Director  
Peter J. Griffin, M.D., F.A.C.S.  
William P. McCann, M.D., F.A.C.S.  
Bruce R. Cook, M.D., F.A.C.S.  
Henry V. Tsai, M.D., F.A.C.S.  
K. Sadasivara Narasim, M.D., F.R.C.S.  
Katharine Creek, M.D., Ph.D.  
Bronker D. Storey, F.A.C.  
David R. Novick, F.A.C.

Division of Orthopedic Spine Surgery  
Joseph E. Weintraub, M.D.

Division of Neurology  
Neurology  
Jonathan S. Morey, M.D.  
Neurology/Epileptology  
Jonathan Reis, M.D.  
Aya Farahmand, M.D.  
Lenny T. Lee, M.D., Ph.D.

Neurology/Neurovascular Disorders  
Jennifer Griffin, M.D.  
Min Zhu, M.D., Ph.D.

Neurology/Movement Disorders  
Shabbir A. Abbasi, M.D. MRCP (UK)

Neurology/Neuro-Oncology  
Vladan P. Milosavljevic, M.D.

Neurology/Vascular Neurology  
Andrew P. Schorck, M.D.  
Jason C. Viereck, M.D., Ph.D.

Division of Pediatric Neurology  
Neurology/Clinical Neurophysiology  
Myrta I. Utero, M.D.

Division of Rheumatology  
Maosong Qi, M.D., Ph.D.

Division of Physical Medicine & Rehabilitation  
Physiatry  
Eduardo P. Cerundano, M.D.  
Srirangam R. Padmanabhan, M.D.  
Scott R. Montjoye, M.D. CIME  
Thomas P. Condy, M.D.  
Salony M. Malmudar, M.D.

Physiatry/Neurological Medicine  
Jon Muzler, M.D., MPH

Division of Pain Medicine  
Anesthesiology  
Jeffrey A. Norton, M.D.  
Michael C. Connolly, M.D.  
Richard R. Riccardi, M.D.  
Karane N. Ngole, F.A.C.

Division of  
Neuro-Behavioral Medicine

Psychiatry  
Marc M. Sudrowsky, M.D.

Psychology  
Robert A. Moverman, Ph.D.

Administration  
Joan L. Faucher  
Administrator/CEO

## EEG REPORT

NAME: NARENDRA JANA

DOB: 10/27/1984

DATE OF STUDY: 01/06/2016

REASON FOR STUDY: Confusion

## SUMMARY OF THE STUDY

Well organized and sustained medium voltage and reactive 8-9 Hz activity was seen symmetric in the posterior head regions. Symmetrical fast activity was seen anteriorly. No focal or epileptiform abnormalities were noted. During photic stimulation, normal occipital driving response was obtained.

IMPRESSION: This EEG is normal with the patient awake.

Vladan P. Milosavljevic, M.D.

msg/t: 1/12/2016 Copy retained for our files.

Serving New England Since 1969

10 College Street, Suite 300 One Palace  
Lowell, MA 01852 Haverhill, MA 01830  
(978) 438-1463 (978) 373-9733

Doctors' Office Building  
21 Highland Avenue  
Newburyport, MA 01950  
(978) 465-3033

Medical Arts Building  
146 Kenney Street  
Nashua, NH 03061  
(603) 882-2114

West Campus  
29 Northwest Blvd  
Nashua, NH 03063  
(603) 579-0770

198 Littleton Road  
Suite 203  
Westford, MA 01886  
(978) 577-1790

In this instance all three clinical diagnostics are most likely fraudulated.

## Dr. Maosong Qi:

The blood tests are done in the same clinic but under a different doctor, Dr. Maosong Qi, who is a Rheumatologist. It was determined to be falsified due to ongoing disease process.

In January 13<sup>th</sup> 2016 a blood test is done in a Dermatology clinic that shows elevated sedimentation rate:

Adult & Pediatric Dermatology, PC  
54 Baker Avenue Extension Suite 305-306, Concord MA 01742  
978-371-7010 Fax: 978-287-4268

Re: NARENDRA JANA DOB: 10/27/1984 Emerson MRN: 717824  
Clinical Service Date: January 13, 2016

01/13/2016 - Lab Report: COMPLETE BLOOD COUNT WITH DIFF, ERYTHROCYTE  
SEDIMENTATION RATE  
Provider: Jennifer P Toyohara MD  
Location of Care: Emerson Hospital Outpatient

Patient: NARENDRA JANA  
ID: LAB 717924  
Note: All result statuses are Final unless otherwise noted.

Tests: (1) COMPLETE BLOOD COUNT WITH DIFF (CBCD)  
! Test- Result Units Reference  
WHITE BLOOD CELL COUNT [H] 11.8 10<sup>3</sup>/mm<sup>3</sup> 4.0-10.0  
RED BLOOD CELL COUNT [L] 4.53 10<sup>6</sup>/mm<sup>3</sup> 3.9-5.5  
HEMOGLOBIN [L] 13.3 g/dL 13.6-16.1  
HEMATOCRIT 39.8 % 39.8-52.0  
PLATELET COUNT ONLY 424 K/mm<sup>3</sup> 140-450  
% NEUTROPHILS 71.6 % 42-75  
% LYMPHOCYTES 21.1 % 20-44  
% MONOCYTES 6.1 % 0-12  
% EOSINOPHILS 0.7 % 0-7  
% BASOPHILS 0.5 % 0-3  
ABSOLUTE NEUTROPHIL COUNT [H] 8.5 10<sup>3</sup>/mm<sup>3</sup> 1.8-7.7  
ABSOLUTE LYMPHOCYTE COUNT 2.5 10<sup>3</sup>/mm<sup>3</sup> 1.0-4.0  
ABSOLUTE MONOCYTE COUNT 0.7 10<sup>3</sup>/mm<sup>3</sup> 0-0.8  
ABSOLUTE EOSINOPHIL COUNT 0.1 10<sup>3</sup>/mm<sup>3</sup> 0-0.45  
ABSOLUTE BASOPHIL COUNT 0.1 10<sup>3</sup>/mm<sup>3</sup> 0-0.30  
MEAN CORPUSCULAR VOLUME 87.9 fL 80-99  
MEAN CORPUSCULAR HEMOGLOBIN 29.3 pg 26-34  
MEAN CORPUSCULAR HGB CONC. 33.3 % 30.0-35.9  
RBC DISTRIBUTION WIDTH 14.0 % 11.5-14.5  
MEAN PLATELET VOLUME 8.4 um<sup>3</sup> 7.4-10.4  
Tests: (2) ERYTHROCYTE SEDIMENTATION RATE (ESR)  
! Test- Result Units Reference  
ERYTHROCYTE SEDIMENTATION RATE [H] 86 mm/Hr 0-14  
Tests: (3) RENAL FUNCTION PANEL (LFT)  
! Test- Result Units Reference  
TOTAL PROTEIN 6.4 gm/dL 6.4-8.3  
ALBUMIN [L] 3.1 gm/dL 3.4-5.5  
BILIRUBIN, TOTAL 0.4 mg/dL 0.3-1.2  
BILIRUBIN, DIRECT 0.1 mg/dL 0.0-0.2  
ALKALINE PHOSPHATASE 87 U/L 35-136  
AST (SGOT) 16 U/L 15-40  
ALT (SGPT) 23 U/L 13-61

The normal sedimentation rate is 0-14 mm/Hr, my sedimentation rate is 86 mm/Hr.

Adult & Pediatric Dermatology, PC  
54 Baker Avenue Extension Suite 305-306, Concord MA 01742  
978-371-7010 Fax: 978-287-4268

Re: NARENDRA JANA DOB: 10/27/1984 Emerson MRN: 717824  
Clinical Service Date: January 13, 2016

Tests: (4) BASIC METABOLIC PANEL (BASP)  
! Test- Result Units Reference  
SODIUM 142 mEq/L 135-145  
POTASSIUM 4.2 mEq/L 3.5-5.5  
CHLORIDE 103 mEq/L 99-113  
CARBON DIOXIDE 31 mEq/L 22-34  
ANION GAP 8 mEq/L 2-13  
GLUCOSE 86 mg/dL 70-100  
BLOOD UREA NITROGEN 11 mg/dL 9-23  
CREATININE 0.8 mg/dL 0.5-1.3  
CALCIUM 8.5 mg/dL 8.3-10.3

Tests: (5) GFR ESTIMATED (CALC) (GFR)  
! Test- Result Units Reference  
GFR ESTIMATED (CALC) > 60 \*\*\* > 60  
Reference: > 60 ml/min/1.73m<sup>2</sup>  
Multiply result by 1.210 if patient is African American.

Tests: (6) TRIGLYCERIDES (TRIG)  
! Test- Result Units Reference  
TRIGLYCERIDES 64 mg/dL 30-150

Note: An exclamation mark (!) indicates a result that was not dispersed into the flow sheet.  
Document Creation Date: 01/13/2016 11:10 PM

(1) Order result status: Final  
Collection or observation date-time: 01/13/2016 15:30  
Requested date-time:  
Receipt date-time: 01/13/2016 18:46  
Reported date-time: 01/13/2016 19:24  
Referring Physician:  
Ordering Physician: JENNIFER TOYOHARA (JTOYOHARA)  
Specimen Source:  
Source: LAB  
Filler Order Number: 0113:H00232R:CBSD  
Lab site: ML, EMERSON HOSPITAL LABORATORY  
(2) Order result status: Final  
Collection or observation date-time: 01/13/2016 15:30  
Requested date-time:  
Receipt date-time: 01/13/2016 18:46  
Reported date-time: 01/13/2016 20:52  
Referring Physician:  
Ordering Physician: JENNIFER TOYOHARA (JTOYOHARA)  
Specimen Source:  
Source: LAB  
Filler Order Number: 0113:H00232R:ESR  
Lab site: ML, EMERSON HOSPITAL LABORATORY  
(3) Order result status: Final  
Collection or observation date-time: 01/13/2016 15:30  
Requested date-time:

Adult & Pediatric Dermatology, PC  
54 Baker Avenue Extension Suite 305-306, Concord MA 01742  
978-371-7010 Fax: 978-287-4268

Re: NARENDRA JANA DOB: 10/27/1984 Emerson MRN: 717924  
Clinical Service Date: January 13, 2016

Receipt date-time: 01/13/2016 18:46  
Reported date-time: 01/13/2016 19:16  
Referring Physician:  
Ordering Physician: JENNIFER TOYOHARA (JTOYOHARA)  
Specimen Source:  
Source: LAB  
Filler Order Number: 0113:C00290R:LFT  
Lab site: ML, EMERSON HOSPITAL LABORATORY

(4) Order result status: Final  
Collection or observation date-time: 01/13/2016 15:30  
Requested date-time:  
Receipt date-time: 01/13/2016 18:46  
Reported date-time: 01/13/2016 19:16  
Referring Physician:  
Ordering Physician: JENNIFER TOYOHARA (JTOYOHARA)  
Specimen Source:  
Source: LAB  
Filler Order Number: 0113:C00290R:RASMP  
Lab site: ML, EMERSON HOSPITAL LABORATORY

(5) Order result status: Final  
Collection or observation date-time: 01/13/2016 15:30  
Requested date-time:  
Receipt date-time: 01/13/2016 18:46  
Reported date-time: 01/13/2016 19:16  
Referring Physician:  
Ordering Physician: JENNIFER TOYOHARA (JTOYOHARA)  
Specimen Source:  
Source: LAB  
Filler Order Number: 0113:C00290R:GFR  
Lab site: ML, EMERSON HOSPITAL LABORATORY

(6) Order result status: Final  
Collection or observation date-time: 01/13/2016 15:30  
Requested date-time:  
Receipt date-time: 01/13/2016 18:46  
Reported date-time: 01/13/2016 19:16  
Referring Physician:  
Ordering Physician: JENNIFER TOYOHARA (JTOYOHARA)  
Specimen Source:  
Source: LAB  
Filler Order Number: 0113:C00290R:TRIG  
Lab site: ML, EMERSON HOSPITAL LABORATORY

-----  
The following lab values were dispersed to the flowsheet  
with no units conversion:

MEAN PLATELET VOLUME, 8.4 UM\*3, (F) expected units: fL  
SODIUM, 142 MEQ/L, (F) expected units: mmol/L  
CARBON DIOXIDE, 31 MEQ/L, (F) expected units: mmol/L  
-----

Adult & Pediatric Dermatology, PC  
54 Baker Avenue Extension Suite 305-306, Concord MA 01742  
978-371-7010 Fax: 978-287-4268

Re: NARENDRA JANA DOB: 10/27/1984 Emerson MRN: 717924  
Clinical Service Date: January 13, 2016

The following non-numeric lab results were dispersed to  
the flowsheet even though numeric results were expected:


GFR ESTIMATED (CALC), > 60  
-----

The following results were not dispersed to the flowsheet:

Test-, Result Units, (F)  
Test-, Result Units, (F)  
Test-, Result Units, (F)  
Test-, Result Units, (F)  
Test-, Result Units, (F)  
Test-, Result Units, (F)

Electronically Signed by Jennifer P Toyohara MD on 01/14/2016 at 2:37 PM  
-----



**Jana, Narendra N**

31 Y old Male, DOB: 10/27/1984  
Account Number: 102119773  
134 Drumlin Hill Rd., Bolton, MA-01740  
Home: 781-223-5780  
Insurance: BLUE SHIELD  
OF MA Payer ID: 64222  
Referring: Referred Self  
Appointment Facility: NENA LAOFC

Guarantor: Jana, Narendra N  
Referring: Referred Self  
Appointment Facility: NENA LAOFC

02/08/2016

Progress Notes: Maosong Qi, MD, Ph.D

**Current Medications****Taking**

- PrednisONE 10 mg Tablet 1 tablet with food or milk twice a day (bid)
- Methotrexate 2.5 MG Tablet 1 to 2 tabs once a week
- Minocycline 100 MG Capsule 1 capsule every 12 hrs
- Vitamin D 2000 UNIT Tablet
- Medication List reviewed and reconciled with the patient

**Past Medical History**

Unremarkable

**Surgical History**

No Surgical History documented.

**Family History**

Father: alive, healthy  
Mother: alive

**Social History**

Tobacco use:  
Smoking status : nonsmoker.  
Alcohol use:  
Drinks alcohol: no.

**Allergies**

N.K.D.A.

**Hospitalization/Major**

Diagnostic Procedure  
No Hospitalization History.

**Review of Systems****-GI ROS:**

Constitutional: denies, fever, fatigue, night sweats or recent weight loss.  
HEENT: denies, headache, vision change, hearing loss, sore throat.  
Resp: denies, cough, shortness of breath. CVS: denies, chest pain, palpitations. GI: denies, heart burn,

**Reason for Appointment**

1. Auto immune

**History of Present Illness****-Present and Interim History:**

2/8/16: Narendra Jana is a 31-year-old male who is referred to me for evaluation of autoimmune disease. He is here alone for his consult visit. He has mental variation for about 7-8 years. He had seen different specialists including psychiatrist and neurologist. Brain imaging tests in the past suspected decreased circulation/oxygen supply. He tried various medications for psychologic issues but none of them helped. He went to California to see a specialist who started him on prednisone and methotrexate. He reports that his mental status became more stable after starting to take prednisone. He has a frequent headache associated with mental variation. Mild joint pain and tingling. He has acne but no other skin rash.

**Vital Signs**

Ht 67, Wt 105, BMI 16.44, BP 123/79, Pulse sitting 102.

**Examination****RHEUM General Exam:**

CONSTITUTIONAL: Thin built, no acute distress. HEENT: PERRL, EOMI, ears normal, nose normal, oropharynx normal, lids/conjunctiva normal. CARDIOVASCULAR: RRR, No M, R, G. LUNGS: lungs clear to auscultation. ABDOMEN: bowel sounds normal, nontender, no hepatosplenomegaly. SKIN: Acnes and hyperpigmentation at face, back and upper front chest. No telangiectasia, no nodules. NEUROLOGICAL: strength normal, no thenar atrophy. HEME/LYMPHATIC: no adenopathy in neck. PSYCH: Affect normal, Alert, Oriented x 3. SPINE: no deformity, ROM normal. MUSCULOSKELETAL: no tenderness on palpation. JOINTS: no deformity, tenderness, erythema, warmth, or effusions on both upper extremity and lower extremity joints.. DATA: Labs reviewed, done on 1/13/16. WBC 11.8, hemoglobin 13.3, platelet 434. CMP unremarkable except albumin 3.1. Sedimentation rate 86..

**Assessments**

nausea, vomiting, diarrhea.  
GU: denies, dysuria, hematuria.  
Skin: Positive for acne, denies, lesions. MSK: reports, pain.  
Neuro: denies, seizure, weakness, tingling. Hematologic: denies, bleeding, enlarged lymph nodes.  
Psychiatric: denies, depression, anxiety.

1. Mental confusion - R41.0 (Primary)
2. Pain in joint - M25.50
3. Paresthesia - R20.2

2/8/16: This is a 31-year-old male who has mental moderation for about 8 years. Lab test done in 2014 shows negative Lupus labs and negative rheumatoid factor. Recent labs shows elevated ESR. He reports benefit to corticosteroid. Based on his history and physical examination, I don't see evidence of autoimmune disease. Given his response to corticosteroid added recently elevated ESR, will order labs for further evaluation. I recommended him to increase methotrexate dose and cutdown prednisone when he feels better. He will travel from this Sunday and will come back in the middle of March.

**Treatment****1. Mental confusion****LAB: CBC (INCLUDES DIFF/PLT)**

WHITE BLOOD CELL COUNT	7.9	3.8-10.8 - Thousand/uL
RED BLOOD CELL COUNT	4.92	4.20-5.80 - Million/uL
HEMOGLOBIN	14.5	13.2-17.1 - g/dL
HEMATOCRIT	44.6	38.5-50.0 - %
MCV	90.7	80.0-100.0 - fL
MCH	29.4	27.0-33.0 - pG
MCHC	32.4	32.0-36.0 - g/dL
RDW	17.6 H	11.0-15.0 - %
PLATELET COUNT	210	140-400 - Thousand/uL
NEUTROPHILS	51.5	- %
ABSOLUTE NEUTROPHILS	4069	1500-7800 - cells/uL
LYMPHOCYTES	34.9	- %
ABSOLUTE LYMPHOCYTES	2757	850-3900 - cells/uL
MONOCYTES	8.9	- %
ABSOLUTE MONOCYTES	703	200-950 - cells/uL
EOSINOPHILS	4.1	- %
ABSOLUTE EOSINOPHILS	324	15-500 - cells/uL
BASOPHILS	0.6	- %
ABSOLUTE BASOPHILS	47	0-200 - cells/uL
MPV	8.2	7.5-11.5 - fL

This lab was reviewed by Maosong Qi on 02/12/2016 at 12:49 PM EST

**LAB: URINALYSIS, COMPLETE**

COLOR	YELLOW	YELLOW -
APPEARANCE	TURBIDA	CLEAR -
BILIRUBIN	NEGATIVE	NEGATIVE -
KETONES	NEGATIVE	NEGATIVE -
SPECIFIC GRAVITY	1.020	1.001-1.035 -
OCCULT BLOOD	NEGATIVE	NEGATIVE -
PH	7.0	5.0-8.0 -
PROTEIN	NEGATIVE	NEGATIVE -
NITRITE	NEGATIVE	NEGATIVE -
LEUKOCYTE ESTERASE	NEGATIVE	NEGATIVE -

Patient: Jana, Narendra N DOB: 10/27/1984 Progress Note: Maosong Qi, MD, Ph.D 02/08/2016  
Note generated by eClinicalWorks EMR/PM Software (www.eClinicalWorks.com)

<http://192.168.100.83:8080/mobiledoc/jsp/catalog/xml/printChartOptions.jsp?encounterID...> 3/22/2019

Patient: Jana, Narendra N DOB: 10/27/1984 Progress Note: Maosong Qi, MD, Ph.D 02/08/2016  
Note generated by eClinicalWorks EMR/PM Software (www.eClinicalWorks.com)

<http://192.168.100.83:8080/mobiledoc/jsp/catalog/xml/printChartOptions.jsp?encounterID...> 3/22/2019



WBC	NONE	< OR = 5 - /HPF
RBC	SEEN	< OR = 2 - /HPF
SQUAMOUS EPITHELIAL CELLS	NONE	< OR = 5 - /HPF
BACTERIA	NONE	NONE SEEN - /HPF
HYALINE CAST	SEEN	NONE SEEN - /LPF
GLUCOSE	NEGATIVE	NEGATIVE -

This lab was reviewed by Maosong Qi on 02/12/2016 at 12:50 PM EST

**LAB: SED RATE BY MODIFIED WESTERGREN**  
SED RATE BY MODIFIED 9 < OR = 15 - mm/h

This lab was reviewed by Maosong Qi on 02/12/2016 at 12:50 PM EST

**LAB: C-REACTIVE PROTEIN**  
C-REACTIVE PROTEIN <0.10 <0.80 - mg/dL

This lab was reviewed by Maosong Qi on 02/12/2016 at 12:49 PM EST

**LAB: RHEUMATOID FACTOR**  
RHEUMATOID FACTOR 11 <14 - IU/mL

This lab was reviewed by Maosong Qi on 02/12/2016 at 12:50 PM EST

**LAB: TSH W/REFLEX TO FT4**  
TSH W/REFLEX TO FT4 0.91 0.40-4.50 - mIU/L

This lab was reviewed by Maosong Qi on 02/12/2016 at 12:49 PM EST

**LAB: ANCA SCREEN WITH MPO AND PR3 WITH REFLEX TO ANCA TITER**

MYELOPEROXIDASE ANTIBODY	<1.0	- AI
PROTEINASE-3 ANTIBODY	<1.0	- AI

This lab was reviewed by Maosong Qi on 02/12/2016 at 15:08 PM EST

**LAB: ANA IFA PANEL COMPREHENSIVE**

ANA SCREEN, IFA	NEGATIVE	NEGATIVE -
SM ANTIBODY	<1.0	<1.0 NEG - AI
SJOGREN'S ANTIBODY (SS-B)	<1.0	<1.0 NEG - AI
SJOGREN'S ANTIBODY (SS-A)	<1.0	<1.0 NEG - AI
SM/RNP ANTIBODY	<1.0	<1.0 NEG - AI
SCL-70 ANTIBODY	<1.0	<1.0 NEG - AI
DNA (DS) ANTIBODY	<1	- IU/mL

This lab was reviewed by Maosong Qi on 02/12/2016 at 15:08 PM EST This lab was reviewed by Maosong Qi on 02/12/2016

Patient: Jana, Narendra N DOB: 10/27/1984 Progress Note: Maosong Qi, MD, Ph.D 02/08/2016  
Note generated by eClinicalWorks EMR/PM Software (www.eClinicalWorks.com)

<http://192.168.100.83:8080/mobiledoc/jsp/catalog/xml/printChartOptions.jsp?encounterID...> 3/22/2019

Erythrocyte sedimentation rate and c-reactive protein are reported to be normal approximately a month after the first test but due to ongoing disease process its not medically possible. The condition is prominent and persistent even when abroad a 2 months later.

There are pictures included in the USB drive of external physical inflammation in Bangkok and Malaysia (soon after this test) to how the condition is persistent.

at 21:39 PM EST

**LAB: COMPREHENSIVE METABOLIC PANEL**

GLUCOSE	92	65-99 - mg/dL
UREA NITROGEN (BUN)	14	7-25 - mg/dL
CREATININE	0.80	0.60-1.35 - mg/dL
eGFR NON-AFR. AMERICAN	119	> OR = 60 - mL/min/1.73m2
eGFR AFRICAN AMERICAN	138	> OR = 60 - mL/min/1.73m2
BUN/CREATININE RATIO	NOT APPLICABLE	6-22 - (calc)
SODIUM	138	135-146 - mmol/L
POTASSIUM	4.4	3.5-5.3 - mmol/L
CHLORIDE	102	98-110 - mmol/L
CARBON DIOXIDE	28	19-30 - mmol/L
CALCIUM	9.4	8.6-10.3 - mg/dL
PROTEIN, TOTAL	6.9	6.1-8.1 - g/dL
ALBUMIN	4.5	3.6-5.1 - g/dL
GLOBULIN	2.4	1.9-3.7 - g/dL (calc)
ALBUMIN/GLOBULIN RATIO	1.9	1.0-2.5 - (calc)
<b>BILIRUBIN, TOTAL</b>	<b>1.3</b>	<b>0.2-1.2 - mg/dL</b>
ALKALINE PHOSPHATASE	55	40-115 - U/L
AST	18	10-40 - U/L
ALT	16	9-46 - U/L

This lab was reviewed by Maosong Qi on 02/12/2016 at 12:50 PM EST

Notes: Order labs as above;  
Increase methotrexate to 7.5 mg once a week;  
Continue prednisone 10 mg twice a day.

**2. Others**

Notes: Patient education was printed.

**Follow Up**

6 Weeks



Electronically signed by Maosong Qi, M.D., Ph.D on  
02/08/2016 at 01:29 PM EST

Sign off status: Completed

Patient: Jana, Narendra N DOB: 10/27/1984 Progress Note: Maosong Qi, MD, Ph.D 02/08/2016  
Note generated by eClinicalWorks EMR/PM Software (www.eClinicalWorks.com)

<http://192.168.100.83:8080/mobiledoc/jsp/catalog/xml/printChartOptions.jsp?encounterID...> 3/22/2019

